

## Dissociation between mental imagery and object recognition in a brain-damaged patient

Marlene Behrmann\*†‡, Gordon Winocur\*†§  
& Morris Moscovitch\*†

\* Rotman Research Institute of Baycrest Centre, 3560 Bathurst Street, Toronto, Ontario M6A 2E1, Canada

† Department of Psychology, Erindale College, University of Toronto, Mississauga, Ontario L5L 1C6, Canada

‡ Faculty of Medicine, University of Toronto, 88 College Street, Toronto, Ontario M5G 1L4, Canada

§ Department of Psychology, Trent University, Peterborough, Ontario K9J 7B8, Canada

**VISUAL imagery is the creation of mental representations that share many features with veridical visual percepts. Studies of normal and brain-damaged people reinforce the view that visual imagery and visual perception are mediated by a common neural substrate and activate the same representations<sup>1-4</sup>. Thus, brain-damaged patients with intact vision who have an impairment in perception should have impaired visual imagery. Here we present evidence to the contrary from a patient with severely impaired object recognition (visual object agnosia) but with normal mental imagery. He draws objects in considerable detail from memory and uses information derived from mental images in a variety of tasks. In contrast, he cannot identify visually presented objects, even those he has drawn himself. He has normal visual acuity and intact perception of equally complex material in other domains. We conclude that rich internal representations can be activated to support visual imagery even when they cannot support visually mediated perception of objects.**

C.K. is a 33-year-old, right-handed man who emigrated from England to Canada in 1980. C.K. presented with a severe deficit in object perception following a closed head injury sustained in a motor vehicle accident in 1988. Premorbidly, C.K. was enrolled in a Master's degree in history which he recently completed with special educational aids. C.K. has a partial left homonymous hemianopia and his visual acuity is 6/7.5 with corrective lenses. No focal lesion is seen on either computed tomography scan (December 1991) or magnetic resonance imaging scan (June 1992) although there is a suggestion of thinning of the occipital lobes bilaterally. The right lateral ventricle was slightly larger than the left but this difference was considered to be within normal limits.

C.K. was able to identify only 18/60 black and white line drawings from a standardized test on which age- and schooling-

matched normal performance is 57/60 (ref. 5). For example, in the Boston Naming test: an asparagus was identified as "a rose twig with thorns", a tennis racquet as "a fencer's mask" and a dart as "a feather duster". His errors indicate that, like some other visual agnosic patients<sup>6,7</sup>, he proceeds in a piecemeal fashion, reconstructing elements of the stimulus and then inferring the object's identity rather than recognizing the object as a meaningful whole. When presented with three-dimensional common objects, he correctly named 11/23 (normal performance 23/23), calling a saw "a knife", pliers "a clothes peg" and a padlock "an earring". With visually presented letters, he was unable to identify any; however, he could identify all of them with perfect accuracy when permitted to trace them. It is unlikely that the deficit depends on the size of the stimulus. C.K. was impaired when stimuli, both letters and pictures, ranged in size from a few millimetres to several centimetres.

Because C.K. named all the objects when he could palpate them with his eyes closed, the object perception deficit cannot be explained by a difficulty in recalling the names of the objects nor can it be attributed to a loss of knowledge of what the objects are. He can provide detailed verbal definitions for objects: for example, he defined a duck as "an animal, marine life, with webbed feet and a bill". The deficit in object recognition also cannot be explained by a global perceptual impairment. Remarkably, C.K.'s ability to identify faces is preserved. He easily recognizes famous people from photographs, even those that make identification difficult. Also, he scored 49 out of 54 (mean for normal males is 46) on a difficult standardized face recognition test that includes matching faces photographed in front and three-quarter view, or under poor lighting conditions<sup>8</sup>. His preserved face recognition suggests that he can adequately perceive and identify stimuli that are at least as complex as the objects he is unable to recognize.

Despite his profound deficit, C.K. can copy figures accurately although he does so slavishly and segmentally. For example, he copies geometric configurations correctly (Fig. 1a), but draws the segments in an unusual order, suggesting that he cannot appreciate the identity of the objects. Similarly, he can copy text but does so slowly and concretely (Fig. 1b). Together, these symptoms are classical features of visual object agnosia.

In contrast to C.K.'s perceptual deficit, his ability to form mental images is normal. C.K. is particularly good at drawing and he took art classes in high school. He can draw from memory complex objects with rich detail (Fig. 1c). He was even able to provide an accurate rendition of all but one (a seahorse) of the 30 items that he failed to recognize on the Boston Naming test<sup>5</sup>. When shown his own drawings on a subsequent occasion, he was unable to identify any of them. This suggests that despite his severe perceptual deficit, he has retained a long-term representation of the objects which he can then use for drawing<sup>9</sup>.

To assess further his visual imagery, we administered six standard tests that have been used with normal and brain-damaged subjects as tests of mental imagery. On a letter task<sup>10,11</sup>, C.K. was asked to imagine an upper-case letter and to judge whether it has any curved lines (C versus L) or to imagine a lower-case letter and to decide whether the letter has a line ascending above or descending below the body (b versus p). He performed perfectly, scoring 26/26 on each test as do normal subjects. He also scored perfectly (20/20) on a colour imagery task<sup>12</sup>, naming the characteristic colour of common items whose colours are not verbally associated with the item (for example, a football, the inside of a cantaloupe). On a size comparison task<sup>12,13</sup>, in which he judged which of two similar-sized objects was larger, C.K. was able to make the correct judgements in all 16 pairs (for example, a popsicle and a pack of cigarettes, a vase and a hydrant). He scored 20/20 on an animal tails task<sup>12,14</sup> in which he judged whether the animal has a long or short tail relative to its body size (for example, kangaroo, pig) and 20/20 on an animal ears test<sup>14</sup> in which he decided whether the animal has floppy or upright ears (for example, doberman, dachshund).

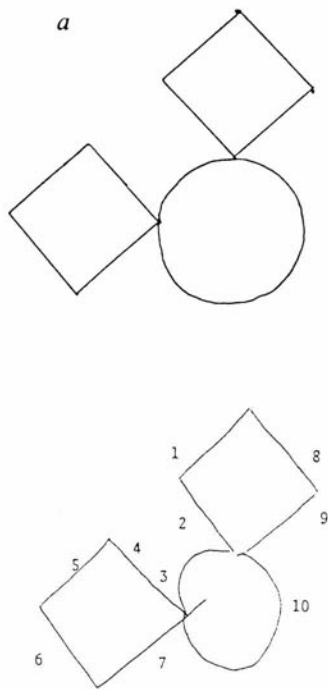
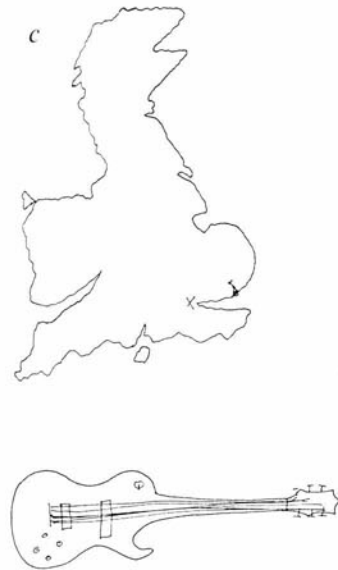

FIG. 1 Examples of C.K.'s performance on various tasks. *a*, Example of C.K.'s copying of geometric configurations. The numbers indicate the sequential order of the strokes. *b*, C.K.'s copying (middle) and spontaneous writing (bottom) of a target sentence (top). Note the difference between the copied letter 'a' which is identical to that in the target stimulus and the letter 'a' produced in spontaneous writing to dictation. *c*, Examples of C.K.'s spontaneous drawings of items from memory: a map of England with 'X' marking his birthplace and an electric guitar.

*b*  
Pack my box with five dozen jugs of liquid veneer.

Pack my box with five dozen jugs of liquid veneer.

Pack my box with five dozen jugs of liquid veneer.



C.K. also performed flawlessly on mental imagery tasks on which his knowledge of distance and spatial layout (rather than an object's appearance) was tested. For example, on a spatial estimation test in which he was given the names of three places (Manchester, Leeds, Birmingham) and had to judge which two are closest together, he scored 20/20. On a clock test<sup>15</sup>, he could decide with perfect accuracy (30/30) whether the angle subtended by the two hands of a clock is larger or smaller than 90 degrees (such as 6.20, 1.35)<sup>19</sup>. Finally, C.K. was given the Brooks letter test<sup>16</sup>, in which he was instructed to imagine a large block-capital letter (E or F) laid out on the ground and to imagine walking clockwise along the outside of the letter, starting on the bottom left corner. He was to report his route and to indicate whether he made right or left turns every time he reached a corner. C.K. indicated only one incorrect turn on this task which was well within normal limits of performance.

C.K. thus has excellent mental imagery despite poor recognition of objects. His perceptual deficit is of central origin as indicated by his intact visual acuity and normal perception of complex stimuli (faces). That he can define objects verbally and identify them by touch suggests that he has retained knowledge of objects he cannot perceive. No other case of such a clear dissociation between impaired object perception and intact imagery has been reported so far.

C.K. complements the reported cases who have intact perception together with impaired mental imagery<sup>17,18</sup>, thus completing both aspects of the double dissociation. Together, these data challenge the prevailing view that a deficit in perception of central origin arises from a loss of the mental representations and the neural structures that mediate them. Our results suggest two alternative hypotheses. One hypothesis is that there are separate underlying representations in long-term memory, one set used for generating mental images and a second set used for perceiving objects. An alternative hypothesis is that there is

a single set of higher-level visual representations with separate routes of access for imagery and for perception. By this view, the dissociation between mental imagery and object perception can arise because access to shared representations cannot be gained either by an internal route for imagery or by an external one for perception. A variant of this view is that there are impairments in intermediate level processes involved in constructing a common representation. Either variant of the latter view is preferred because it provides a unifying and parsimonious account of both manifestations of the double dissociation. *Note added in proof:* Since submission of this letter, a visual agnostic (M.D.) has been described<sup>20</sup> who also shows some preserved imagery despite his perception deficit. □

Received 6 May; accepted 7 August 1992.

1. Farah, M. J. *Psychol. Rev.* **95**, 307-317 (1988).
2. Finke, R. A. *Psychol. Bull.* **98**, 236-259 (1985).
3. Farah, M. J. et al. *J. exp. Psychol.* **117**, 248-257 (1988).
4. Farah, M. J. *Cognition* **18**, 245-251 (1984).
5. Kaplan, E. et al. *Boston Naming Test* (Lea and Febiger, Philadelphia, 1983).
6. Riddoch, M. J. & Humphreys, G. W. *Brain* **110**, 1431-1462 (1987).
7. Graillet, J. M. et al. *Cognitive Neuropsychol.* **7**, 275-310 (1990).
8. Benson, A. L., deS. Hamsher, N., Varney, N. & Spreen, O. *Facial Recognition* (Oxford Univ. Press, New York, 1983).
9. van Sommers, P. *Cognitive Neuropsychol.* **6**, 117-164 (1989).
10. Kosslyn, S. M. et al. *J. exp. Psychol.* **114**, 311-341 (1985).
11. Sergent, J. *J. exp. Psychol. Hum. Percept. Perform.* **15**, 170-178 (1989).
12. Farah, M. J. et al. *Cognitive Psychol.* **20**, 439-462 (1988).
13. Kosslyn, S. M. et al. *J. exp. Psychol.* **106**, 341-376 (1977).
14. Kosslyn, S. M. *Cognitive Psychol.* **7**, 341-370 (1975).
15. Corballis, M. & Sergent, J. *Neuropsychologia* **26**, 12-26 (1988).
16. Brooks, L. R. *Can. J. Psychol.* **22**, 349-368 (1968).
17. Riddoch, M. J. *Cognitive Neuropsychol.* **7**, 249-273 (1990).
18. Farah, M. J. et al. *Brain Cogn.* **8**, 147-164 (1988).
19. Craik, F. I. M. & Dirks, E. *Psychol. Aging* **7**, (in the press).
20. Jankowiak, J., Kinsbourne, M., Shalev, R. & Bachman, D. L. *J. cogn. Neurosci.* **4**, 119-131 (1992).

ACKNOWLEDGEMENTS. This research was supported by grants from the Medical Research Council of Canada and by an Ontario Mental Health Foundation Research Associateship and a Medical Research Council Scholarship to M.M. and to M.B., respectively.